

Variations in the Origin of Medial Circumflex Femoral Artery from Femoral Artery

Dr. V. Lakshmi¹, Dr. J. K Raja^{2*}

¹Associate Professor, Department of Anatomy, Stanley Medical College, No. 1, Old Jail Rd, Old Washermanpet, Chennai, Tamil Nadu, India

²Assistant Professor, Department of Anatomy, Stanley Medical College, No. 1, Old Jail Rd, Old Washermanpet, Chennai, Tamil Nadu, India

*Corresponding author: Dr. J. K Raja

| Received: 02.03.2019 | Accepted: 15.03.2019 | Published: 30.03.2019

DOI: [10.21276/sijap.2019.2.3.5](https://doi.org/10.21276/sijap.2019.2.3.5)

Abstract

The profunda femoris artery is very important branch of femoral artery supplying the thigh. One of its important branches is medial circumflex femoral artery. Knowledge about variation in its origin is important for the surgeons and radiologists. The present study was conducted in 50 embalmed cadavers in the department of Anatomy, Stanley Medical College. The medial circumflex femoral arteries were seen originating from profunda femoris artery in 84 %. In 16% medial circumflex femoral arteries were seen originating from the femoral artery at the same level of profunda femoris artery.

Keywords: Femoral Artery, Profunda Femoris Artery, Medial Circumflex Femoral Artery.

Copyright © 2019: This is an open-access article distributed under the terms of the Creative Commons Attribution license which permits unrestricted use, distribution, and reproduction in any medium for non-commercial use (NonCommercial, or CC-BY-NC) provided the original author and source are credited.

INTRODUCTION

The course and ramification of blood vessels of the lower limb have long been received attention by anatomists and surgeons. The big horizon of the interventional radiology opens new avenues for the study of variations of the profunda femoris artery. This vessel is useful for doppler imaging, arteriography, angiography and also magnetic resonance imaging. The profunda femoris artery is the chief artery of thigh. It gives branches to important anastomoses like trochanteric anastomosis, anastomosis around knee, cruciate anastomosis, chain anastomosis and spinous anastomosis. One of its important branches taking part in anastomosis is medial circumflex femoral artery. The medial circumflex femoral artery usually arises from the postero medial aspect of the profunda femoris artery but of directly from femoral artery. It supplies the muscles of the adductor compartment. It curves medially round the femur between pectineus and psoas major muscles and then the obturator externus and psoas major muscles and then the obturator externus and adductor brevis muscles. Finally it passes between the quadratus femoris and upper border of the adductor magnus muscles, dividing into transverse and ascending branches. The transverse branch takes part in the cruciate anastomosis. The ascending branch ascends on the tendon of the obturator externus muscle, anterior to the quadrates femoris muscle to the trochanteric fossa,

where it anastomose with the branches of gluteal and lateral circumflex femoral arteries. From here, Acetabular branch enter the hip joint under the transverse acetabular ligament supplying the femoral head.

Aim of the study

To find out whether the medial circumflex femoral artery arises from profunda femoris artery or femoral artery.

MATERIALS & METHODS

The present study was conducted in 50 embalmed cadavers preserved with formalin in Department of Anatomy, Govt. Stanley Medical College, chennai. Conventional dissection was carried out.

RESULTS

The source of origin of medial circumflex femoral artery was recorded. In 84 % medial circumflex femoral artery were seen originating from profunda femoris artery. In 16% (Fig 1 & 2) medial circumflex femoral artery was seen originating from the femoral artery at the same level of profunda femoris artery (Chart-1).

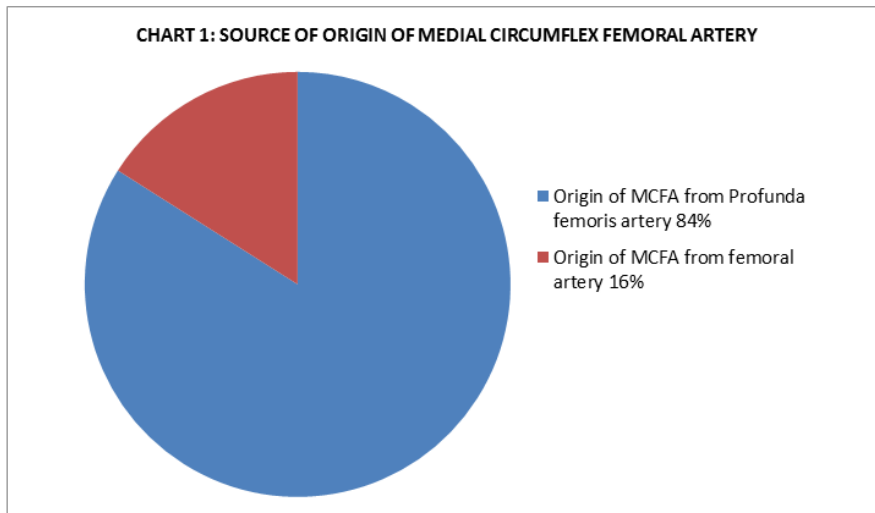


Chart-1: Source of Origin of Medial Circumflex Femoral Artery

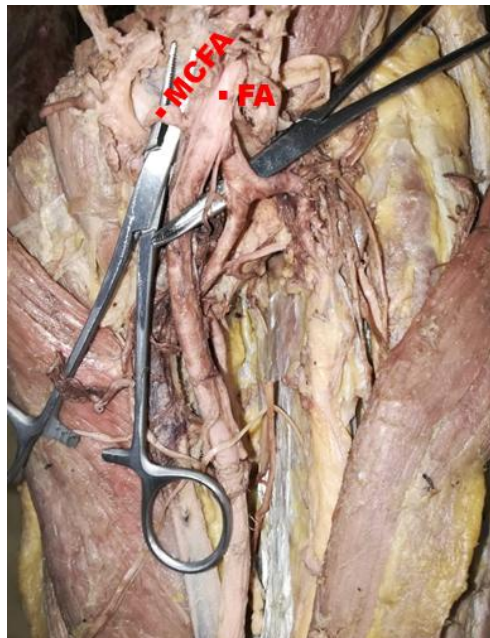


Fig-1: Medial circumflex femoral artery arising from femoral artery – Left thigh

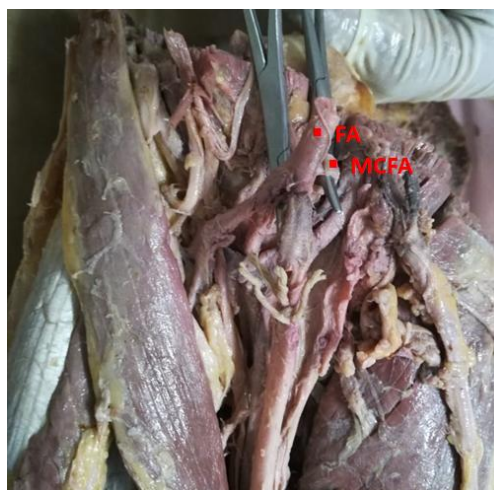


Fig-2: Medial circumflex femoral artery arising from femoral artery – Right thigh
(MCFA- Medial circumflex femoral artery, FA – Femoral artery, PFA - Profunda femoris artery)

DISCUSSION

According to Banister *et al.*, [1] medial circumflex femoral artery arose from profunda femoris artery in 62.5% and from femoral artery in 37.5%. According to Clarke and Colbourn [2] the medial circumflex femoral artery originated 53% from profunda femoris artery and 47% from the femoral artery. According to Lipshutz [3] the medial circumflex femoral artery originated from profunda femoris artery in 59% and from femoral artery in 41%. In the present study in 16% (Fig 1 & 2) medial circumflex femoral artery was seen originating from the femoral artery at the same level of profunda femoris artery. However 84% showed the origin of medial circumflex femoral artery from profunda femoris artery.

CONCLUSION

The medial circumflex femoral artery usually arises from profunda femoris artery, it may also arise directly from femoral artery.

REFERENCES

1. Collins, P., Gray, H., Bannister, L. H., Berry, M. M., & Williams, P. L. (2005). *Gray's anatomy*. Elsevier Churchill Livingstone.
2. Clark, S. M., & Colborn, G. L. (1993). The medial circumflex femoral artery: its clinical anatomy and nomenclature. *Clinical Anatomy*, 6: 94-105.
3. Lipshutz, B. B. (1916). Studies on the blood vascular tree. *The Anatomical Record*, 10(5), 361-370.