

**Consumption of *Mucuna urens* (Ibaba) Alters the Cellular Configuration of the Testes in Male Mice****Gabriel D. Edem<sup>\*</sup>, Uwemedimo G. Udoh**

Department of Anatomy, College of Health Sciences, University of Uyo, Nigeria

**\*Corresponding author***Gabriel D. Edem***Article History***Received: 05.04.2018**Accepted: 18.04.2018**Published: 30.04.2018***DOI:**

10.21276/sb.2018.4.4.5



**Abstract:** Histomorphological assessment of the testes of mice exposed to the ethanolic seed extract of *Mucuna urens* were investigated in 24 male mice weighing between 20 – 30g. The mice were divided into four groups of six mice each. Group 1 was the control, while group 2, 3 and 4 were the experimental groups. 80 seeds of *Mucuna urens* were macerated and the content was extracted using 1000mls of absolute alcohol, filtered and dried in water-bath at 45°C. 1000mg of the extract was dissolved in 50mls of distilled water and 50mls of 30% tween 80. The extract was administered orally for 7 days. Group 1 was administered 5ml distilled water, group 2 were administered 100mg/kg of ethanolic seed extract of *Mucuna urens*, group 3 were administered 200mg/kg of ethanolic seed extract of *Mucuna urens* and group 4 were administered 300mg/kg of ethanolic seed extract of *Mucuna urens*. After sacrifice, the testes was harvested and fixed in 10% buffered formalin, dehydrated in alcohol, cleared in xylene, infiltrated in molten paraffin wax and embedded. The tissues were processed to paraffin sections, cut at 5 microns, stained in H&E staining technique and the cytoarchitecture was viewed with light microscope. Photomicrograph of group 1 showed normal blood vessels, seminiferous tubules and interstitial connective tissues. Photomicrograph of group 2 showed lesion blood vessels, shrinking seminiferous tubule and mild eroded interstitial connective tissues. Photomicrograph of group 3 showed hemorrhage, severely shrinking seminiferous tubules and severely eroded interstitial connectively tissue. Photomicrograph of group 4 showed degenerated blood vessels, degenerated seminiferous tubules and severely eroded interstitial connective tissues. Severity was dependent on dose and duration. The ethanolic seed extract of *Mucuna urens* may lead to fertility impairment by altering the ultrastructure of the testes.

**Keywords:** *Mucuna urens*, Consumption, Histomorphology.

**INTRODUCTION**

*Mucuna urens* or Horse eye bean (Family Fabaceae: Papilionoideae) is found from Nicaragua to South America, and is widespread in Costa Rica from 500-2,000m elevation [1]. This is one of the seven *Mucuna* species in Costa Rica and is most common at high elevations and forest edges [2]. Its common name in Spanish, picapica roughly translates to "itchitch" and refers to the urticating, itchy hairs that cover the flowers and fruit pods [1]. This woody liana has large trifoliate leaves with entire margins and spaced secondary veins, and a swollen pulvinus [3]. It also has asymmetrical veins and leaflets. Because it is a liana, it grows spiraled around other plants in the area. The Horse Eye Bean inflorescence contains zygomorphic, pealike flowers with 10 stamens, and the greenish, cream-colored flowers are arranged in a spiral in groups of three on the stem [1]. This hanging chandelier-like cluster on the liana is found on the end of the peduncles, which can be of varying lengths up to 10 m [4]. Although most members of the Papilionoideae subfamily are pollinated by bees, this

genus is pollinated by bats; specifically, the Horse eye bean is pollinated by the nectivorous small bat *Glossophaga soricina* [4]. *Glossophaga* finds the flowers using an acoustic nectar guide that reflect echolocation signals back to the bat so it can easily find the flower, a technique seen in several *Mucuna* species [5]. The Horse Eye Bean has also been recorded as being pollinated by the omnivorous bat *Anoura caudifer* and *Hylonycteris* species, though not as often as *Glossophaga soricina* [1]. Agostini, Sazima and Sazima [4]; found that as the bats probe for nectar, the flowers project pollen onto the pollinators in an explosive fashion after pressure has been applied to the flower. When this flower opening mechanism is activated, the flower immediately ceases nectar production to begin fruit development [4]. Some bees and hummingbirds have been observed as nectar robbers that drill holes and steal nectar from the flower during the day without pollinating the flower.

The vine of *Mucuna urens* is woody, twining, attaining 30m in length. The stems is cylindrical,

glabrous, smooth, that turns blackish on drying, attaining up to 10cm in diameter at the base and producing a watery sap with a pink color [5].

The Leaves of *Mucuna urens* are alternate, trifoliolate and usually with leaflets which are coriaceous and glabrous. The size of the *Mucuna urens* leaf is 7-14 × 4.5-7cm. The margins of the entire upper surface is dark green, shiny and glabrous and the margins of the entire lower surface is light green

(purple on juvenile leaflets), shiny, glabrous, with prominent puberulent venation. The terminal leaflet is elliptical or oblong and the apex is acuminate, the base is rounded. The lateral leaflets is asymmetrical, elliptic-lanceolate, the apex acuminate, the base unequal and truncate-obtuse. The petiolules is slightly thickened, 5-6 mm long, glabrous or puberulent. The stipels is absent. The petioles is 4-9 cm long, striate and thickened at the base. The stipules are deciduous [5].



Fig-1: *Mucuna urens*

Source: [www.google.com](http://www.google.com)

The testes are the male gonads-paired ovoid reproductive glands that produce sperms (spermatozoa) and male hormones, primarily testosterone. The testes are suspended in the scrotum by the spermatic cords, with the left testis usually suspended (hanging) more inferiorly than the right testis [6].

## MATERIALS AND METHOD

### Collection of *Mucuna* Seeds

*Mucuna urens* seeds were obtained from a local market in Uyo Local Government Area of Akwa Ibom State. The seeds were identified and authenticated in the department of Pharmacy, University of Uyo.

### Experimental Animals

Twenty four male mice, weighing between 20g – 30g were obtained from animal house of Faculty of Basic medical sciences, University of Uyo. They were housed and acclimatized in the animal house for three weeks, under standard laboratory conditions. The mice were divided into four groups (Groups A, B, C and D) containing six mice each. They were housed in rubber cage with metallic meshed covering. The animals were feed daily throughout the course of acclimatization and administration with vital grower mash obtained from local market and clean water were provided ad libitum. The feed and water were provided in stainless plates

and feeding bottles respectively and their faeces were cleaned out from the cages twice weekly.

They were identified by different colour markings on their tails ranging from red, green and black. All the animals were handled and cared for in accordance and in compliance with applicable guidelines and standard for the care and use of laboratory animals.

### Extract Preparation for Administration

The *Mucuna urens* seeds were crushed with grinding stone to remove the epicarp, and the mesocarp was removed with knife leaving the endocarp. These were grinded with grinding machine to obtain a fine powdered particles. The particles were soaked in absolute ethanol of 800 mls for 72 hrs. The crude extract were separate from the suspended particles by filtration. The filtrate was concentrated in water bath of 45°C for 48hrs and stored in refrigerator at 4°C.

The sticky concentrated ethanol free *Mucuna urens* seed extract (1000mg) were mixed with 50ml of water and 50ml of 30% tween 80. Thus 100ml of 15% tween 80 was used to dissolve the extract. The extract was administered orally with the aid of feeding tube

attached to 10ml syringe. The administration was done in accordance to the body weight of the mice.

#### Experimental Design

The animals which were divided into four different groups received dosages as follows:

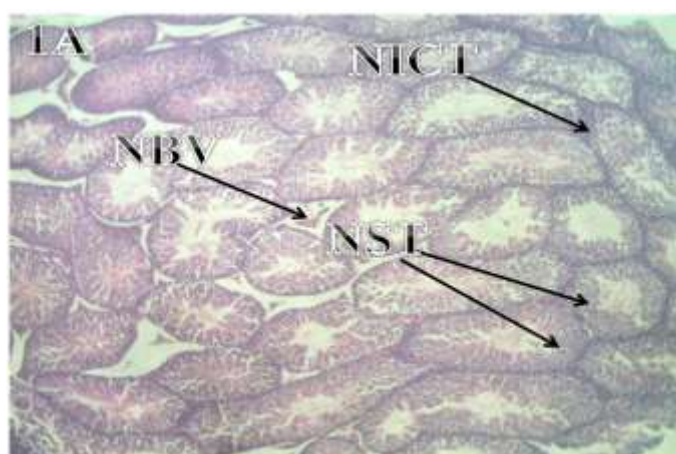
- Group 1 (Control group) was administered with 5ml distilled water.
- Group 2 (Low dose) administered with 100mg/ml of the extract solution.
- Group 3 (Medium dose) administered with 200mg/ml of the extract solution.
- Group 4 (High dose) administered with 300mg/ml of the extract solution.

- Mucuna seed extract were given to the animals for one week

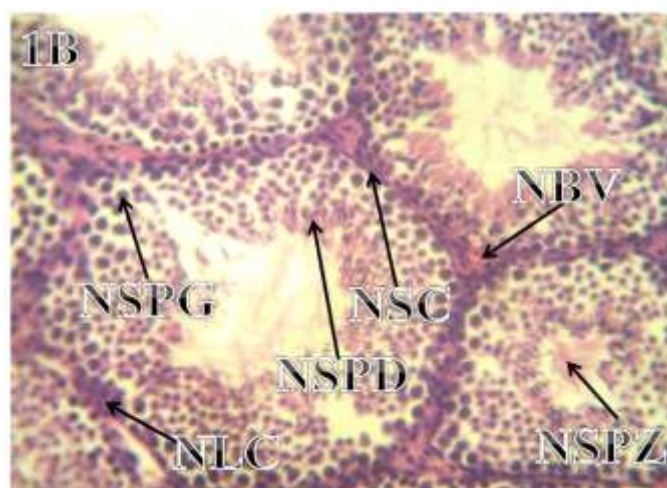
#### Animal sacrifice and Tissue Processing

After one week of administration the animal were weighed again and sacrifice using chloroform vapour. The animals were placed in a glass jar and chloroform vapour was oozed into it. It was covered with thick place glass for 5minutes. After anaesthesia, the animals were placed on a rectangular wooden surface that were sterilized. The testes were surgically removed. The tissues were suspended in 10% buffered formalin as a fixing medium for one week. The tissues were processed histologically and stained using H&E staining methods.

#### RESULTS



**Plate 1A:** Photomicrograph of the testis from mice in group 1 showing normal blood vessels (NBV), normal seminiferous tubules (NST) and normal interstitial connective tissues (NICT). Stained with Haematoxylin and Eosin  $\times 100$  magnification.



**Plate 1B:** Photomicrograph of the testis from mice in group 1 showing normal blood vessels (NBV), normal sertoli cells (NSC), normal leydig cells (NLC), normal spermatogonia cells (NSPG), normal spermatid cell (NSPD) and normal spermatozoa cells (NSPZ). Stained with Haematoxylin and Eosin  $\times 400$  magnification.

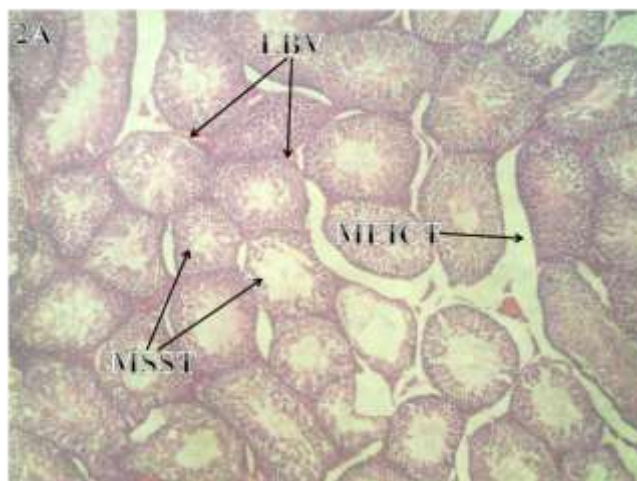


Plate 2A: Photomicrograph of the testis from mice in group 2 administered with 100mg/kg of ethanolic seed extract of *Mucuna urens* showing lesioned blood vessels (LBV), shrinking seminiferous tubule (MSST) and mild eroded interstitial connective tissue (MEITC). Stained with Haematoxylin and Eosin  $\times 100$  magnification.

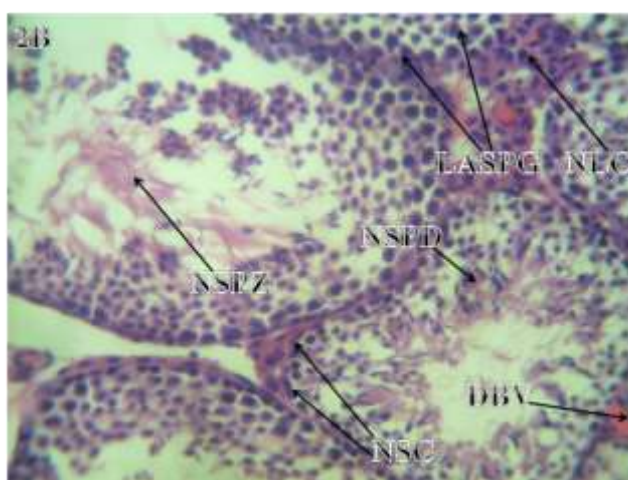


Plate 2B: Photomicrograph of the testis from mice in group 2 administered with 100mg/kg of ethanolic seed extract of *Mucuna urens* showing diffused blood vessels (DBV), normal leydig cells (NLC), normal sertoli cells (NSC), normal spermatozoa (NSPZ), normal spermatid (NSPD) and loosely arranged spermatogonia (LASPG). Stained with Haematoxylin and Eosin  $\times 400$  magnification.

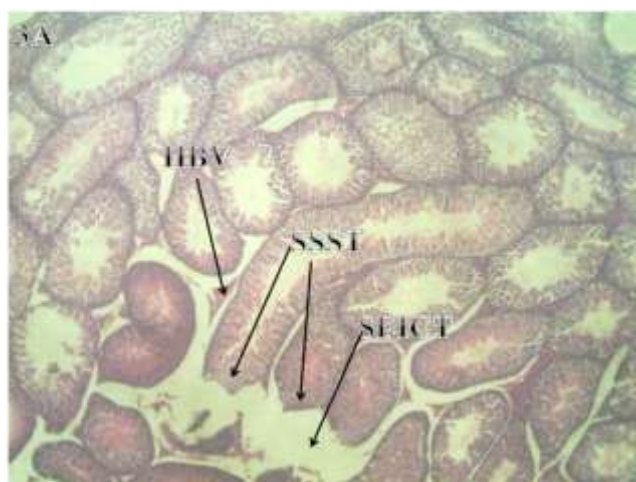
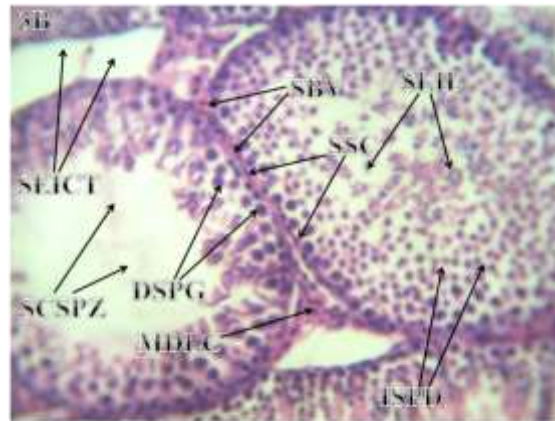
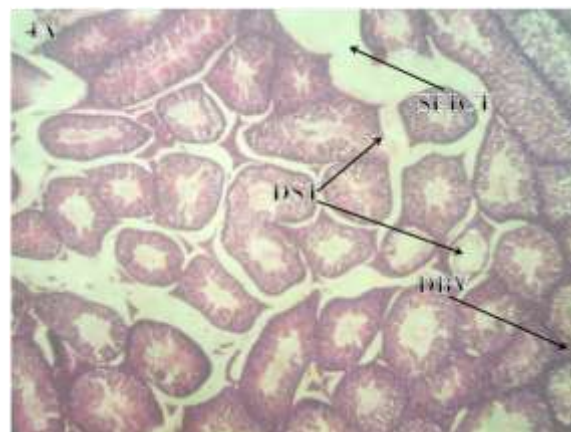


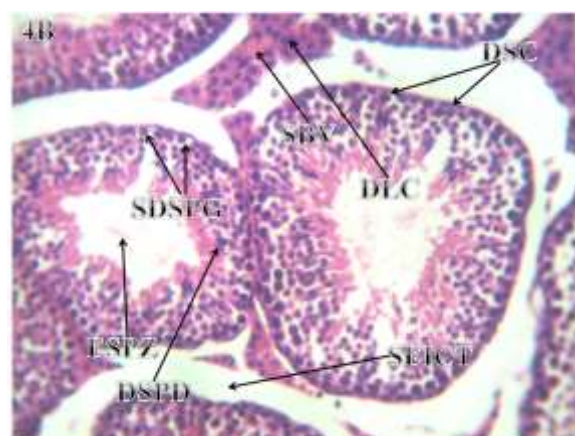
Plate 3A: Photomicrograph of the testis from mice in group 3 administered with 200mg/kg of ethanolic seed extract of *Mucuna urens* showing hemorrhage blood vessels (HBV), severely shrinking seminiferous tubules (SSST) and severely eroded interstitial connective tissue (SEICT). Stained with Haematoxylin and Eosin  $\times 100$  magnification.



**Plate 3B:** Photomicrograph of the testis from mice in group 3 administered with 200mg/kg of ethanolic seed extract of *Mucuna urens* showing shrinking blood vessels (SBV), severely eroded interstitial connective tissue (SEICT), shredding sertoli cells (SSC), decreasing spermatogonia (DSPG), scanty spermatozoa (SCSPZ), mild degenerating leydig cell (MDLC), increasing spermatid (ISPD) and seminiferous lumen infiltrated with leucocyte (SLIL). Stained with Haematoxylin and Eosin  $\times 400$  magnification



**Plate 4A:** Photomicrograph of the testis from mice in group 4 administered with 300mg/kg of ethanolic seed extract of *Mucuna urens* showing degenerating blood vessels (DBV), degenerating seminiferous tubules (DST) and severely eroded interstitial connective tissue (SEICT). Stained with Haematoxylin and Eosin  $\times 100$  magnification



**Plate 4B:** Photomicrograph of the testis from mice in group 4 administered with 300mg/kg of ethanolic seed extract of *Mucuna urens* showing scanty and degenerating blood vessels (DBV), degenerating leydig cell (DLC), degenerating sertoli cell (DSC), severely degenerated spermatogonia (SDSPG), exfoliated spermatozoa (ESPZ), degenerating spermatid (DSPD) and severely eroded interstitial connective tissue (SEICT). Stained with Haematoxylin and Eosin  $\times 400$  magnification

---

From this investigation, the photomicrograph of sections of control mice showed normal blood vessels, normal sertoli cells, normal leydig cells, normal spermatogonia cells, normal spermatid cell and normal spermatozoa cells at lower and higher magnifications. The photomicrograph of sections of mice administered with 100mg/kg of ethanolic seed extract of *Mucuna urens* at lower and higher magnifications showed lesioned blood vessels, shrinking seminiferous tubule, mild eroded interstitial connective tissue and loosely arranged spermatogonia. Sections of mice administered with 200mg/kg of ethanolic seed extract of *Mucuna urens* showing hemorrhage blood vessels, severely shrinking seminiferous tubules, severely eroded interstitial connective tissue, shredding sertoli cells, scanty spermatozoa, mild degenerating leydig cells, increasing spermatids and seminiferous tubule lumen infiltrated with leucocytes at lower and higher magnifications. Similarly sections of testes of mice 300mg/kg of ethanolic seed extract of *Mucuna urens* showing degenerating blood vessels, degenerating seminiferous tubules, severely eroded interstitial connective tissue, severely degenerated spermatozoa, exfoliated spermatozoa and degenerating spermatid at lower and higher magnifications .

## DISCUSSION

The presence of humanity on the earth was accompanied by ailments since man's existence was susceptible to diseases of different causative agent and as such over decades herbs and plant of therapeutic composition have been in used to combat these diseases. Plants of diierent species including *Mucuna urens* have been used for therapeutic purpose. According to De Fillips, Miana and Crepin [7] it has been found that sap from *Mucuna urens* is rubbed on sprains, rheumatic areas, contusions, sore muscles and used for children's fever. The hairs of *Mucuna urens* are mixed in molasses syrup and drunk as a vermifuge to expel intestinal worms, with a chaser of rhubarb juice. Cataplasm of the bark and ground seeds of *Mucuna urens* is recommended for inguinal hernia. Despite these enormous merits, *Mucuna urens* has some demerits according to Udoh and Ekpeyong [8], it is anti-spermatid and the hairs on the pod of the fruit causes itching according to De Fillips, Miana and Crepin [7].

The objective of this research was to investigate the changes in the architectural environment of the testes after consumption of one of the most locally consumed seed extract by some locals in Nigeria. In the control group administered with distilled water showed that the testicular lobules contain normal coilly seminiferous tubules. Each seminiferous tubule is surrounded by a normal interstitial connective tissue in which blood vessels branch through. In between the seminiferous tubule are epithelioid cells called the interstitial cells of Leydig. The photomicrograph of the

control group using a higher magnification also shows that each seminiferous tubule contain germinal epithelium which contain two cells; the supporting cells which is the pyramidal non-proliferative sertoli cells, and the proliferative cell which is the spherical spermatogenic cells. The spermatogenic cells form the primary and secondary spermatocyte through meiotic cell division. Toward the central lumen are normal spermatid which give rise to the spermatozoa at the centre of the lumen [9].

This research showed that the treatment of mice with ethanolic seed extract of *Mucuna urens* produced some pathological changes in the cytoarchitecture of the sections of testes compared to the control group.

The photomicrograph of testes of mice administered 100mg/kg of ethanolic extract of *Mucuna urens*, showed mild shrinking seminiferous tubules of which its surrounding interstitial connective tissue are also mildly eroded. The blood vessels in these eroded connectives tissues are diffused with lesions which may be due to weakening of the tunics caused by alkaloids present in *Mucuna urens* which according to Manfred, 2002 is a sympatomimetic, anti-hypertensive and vasodilators. This implies that hemorrhage occurs leading to reduction in total body fluid volume. Similarly, at higher magnification, the seminiferous tubule germinal epithelium contain normal sertoli cells, spermatid and spermatozoa. In between the seminiferous tubule are normal interstitial cells of Leydig and loosely packed spermatogenic cells. This implies that fertilization may occur only at short duration. This is in consonance with Udoh and Ekpenyong [8]; who determined that the effect of *Mucuna urens* on the gonad of male guinea-pigs, at a low dose of 70mg/kg could cause spermatid arrest at spermatogenic level.

The photomicrograph of testes of the group administered with 200mg/kg of ethanolic extract of *Mucuna urens*, showed severe shrinking seminiferous tubules of which the surrounding interstitial connective tissues were severely eroded. There were blood stain within the interstitial connective tissue caused by haemorrhage which may due to presence of alkaloids which is a vasodilator according to Manfred [10]. At higher magnification, the seminiferous tubule germinal epithelium contain shredding sertoli cells and decreasing spermatogonia. The decrease in spermatogonia may be due to the arrest of meiotic division of spermatogenic cells which results in the reduction in the cell number. This is because the sertoli cells provide nutritive factor for the spermatogenic cells [9]. Toward the lumen, the central part is infiltrated by leucocyte. This infiltration according to Sembulingam and Sembulingam [11] may be due to chemotaxis which causes attraction by chemical

substances called chemoattractant released from the infected area. After reaching the area, the leucocyte surround the area and get adhered to the infected tissues and their increased sticky adhesion is aided by the chemoattractants. These chemoattractants may be the high toxicity of the bioactive ingredient in *Mucuna urens*. Spermatid spread across the seminiferous lumen and occur in the portions of the spermatozoa which may be caused by loss of binding protein. The spermatozoa were degenerated and scanty, even though there was cellular degeneration, there was just mild degenerating leydig cell.

The photomicrograph of testes of mice administered 300mg/kg of ethanolic extract of *Mucuna urens* showed severe degenerating seminiferous tubules of which the surrounding interstitial connective tissues were severely eroded and scanty blood vessels due to necrosis. At high magnification, the primary and secondary spermatocyte are well arranged but the spermatid are degenerating with severe exfoliation of the entire lumen occupied by spermatozoas. There is no tendency of spermatozoa proliferation since the interstitial cells of Leydig are also degenerating. This is in agreement with the research conducted by Udoh and Ekpenyong [8]; on the effect of *Mucuna urens* on guinea-pig at high dose of 140mg/kg which showed from its histological observation complete degeneration of sperm in the testicular lobules.

## CONCLUSION

*Mucuna urens* is a traditional and locally consumed seed used for various purposes, example, the seeds are used as thickening agent in soup and it has therapeutic purposes, example the sap is used for treatment of sore muscle and treatment of fever. The result obtained from this research shows that *Mucuna urens* is anti-spermatogenic at low, medium and high dose but duration dependent. Caution should be imbibed during the consumption of these seeds since it could cause infertility in males.

## COMPETING INTERESTS

Authors have declared that no competing interests exist

## REFERENCES

1. Zuchowski, W. (2005). A guide to Tropical Plants of Costa Rica [Una guía para las plantas tropicales de Costa Rica]. *Florida: Zona Tropical*.
2. Gargiullo, M., & Magnuson, B. (2008). *A field guide to plants of Costa Rica*. Oxford University Press.
3. Gentry, A. H., & Vasquez, R. (1996). *A Field Guide to the Families and Genera of Woody Plants of Northwest South America (Colombia, Ecuador, Peru) with supplementary notes on herbaceous taxa*. University of Chicago Press.
4. Agostini, K., Sazima, M., & Sazima, I. (2006). Bird Pollination of Explosive Flowers while Foraging for Nectar and Caterpillars. *Biotropica*. 38: 674-678.
5. Acevedo-Rodríguez, P. (2005). Vines and climbing plants of Puerto Rico and the Virgin Islands. *Contributions from the United States National Herbarium*, 51, 1-483.
6. Moore, L. K., Dalley F. A., & Agur M. R. A. (2014). *Moore Clinical Oriented Anatomy*. 7th Ed., China: Lippincott Williams and Wilkins, a Wolters Kluwer Business. Pp. 345-47.
7. De Fillips, R. A., Miana, S. L., & Crepin, J. (2004). Medicinal Plants of the Guinas.
8. Udoh, P., & Ekpenyong, J. (2001). Effect of *Mucuna urens* (Horse Eye Bean) on the Gonads of Male Guinea-pigs. *Phytotherapy Research*. John Wiley and sons Limited. 15 (2): 99-102.
9. Eroschenko, V. (2008). *Di\_Fiores Atlas of Histology and Functional Correlations* 11<sup>th</sup> Ed., Lippincott Williams and Wilkins P 413.
10. Manfred, H. (2002). Alkaloids. Natures Curse or Blessing. Willey-VCH, Weinheim, Germany.
11. Sembulingam, K., & Sembulingam P. (2012). *Essentials of Medical Physiology*. 6th Ed., India Pp. 59; 86-7.